

9th Bryan Warren School of Pathology
Pancreatic and Liver Pathology

Slide Seminar – Focal Liver Lesions

Cases 1-5

Stefan Hübscher

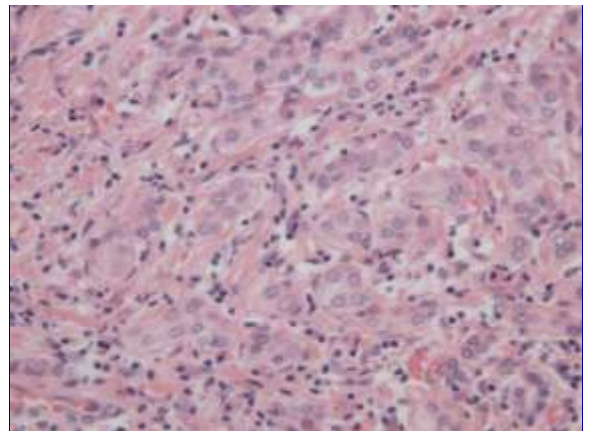
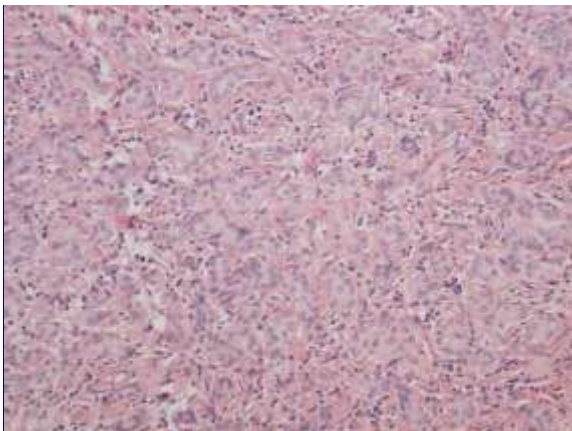
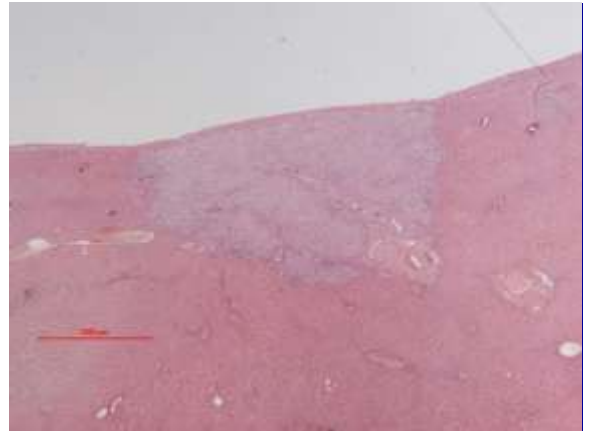
Institute of Immunology & Immunotherapy, University of Birmingham
Dept of Cellular Pathology, Queen Elizabeth Hospital, Birmingham

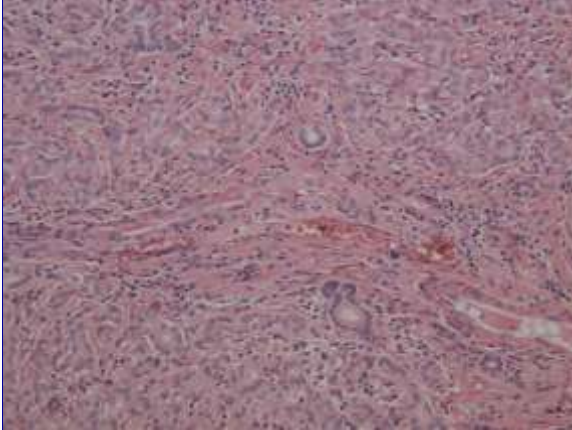
Case 1

Case 1 - Clinical Summary

Male, age 56

- Liver resection for metastatic colorectal carcinoma.
- Incidental small subcapsular lesion 0.5cm diameter in segment 6.





Case 1 – Histological Findings

- Small, slightly irregular glands
- No cytological atypia
- Scanty fibrous stroma containing inflammatory cells
- Incorporated portal tract

Case 1 – Diagnosis

Peribiliary gland hamartoma
(bile duct adenoma)

Case 1 – Discussion Points

1. Nature of lesion (evidence for peribiliary gland origin)

- Topographic relationship to normal bile duct
- Immunohistochemical studies show phenotype of peribiliary glands rather than bile ducts (D10 & 1F6 positive) (Bhathal 1996)
- Similar changes may occur as reaction to localised area of parenchymal extinction (e.g. in cirrhotic livers)
 - “peribiliary gland hyperplasia”
- Minimal malignant potential

BUT

- Recent studies have shown *BRAF* V600E mutations in 55% of cases, suggesting bile duct adenoma is a neoplasm (Pujals Hepatology 2014 & Pujals Histopathology 2015)
- Similar mutations seen in 5% of intrahepatic cholangiocarcinomas

Case 1 – Discussion Points

2. Clinical Presentation

- incidental finding at abdominal surgery
- common indication for frozen section

Case 1 – Discussion Points

3. Features favouring a benign process

- small size
- lack of cytological atypia
- fibrous stroma dense & inflamed (but not desmoplastic)
 - Some lesions may have abundant hyalinised fibrous stroma with relatively scanty glands
- incorporated portal tracts

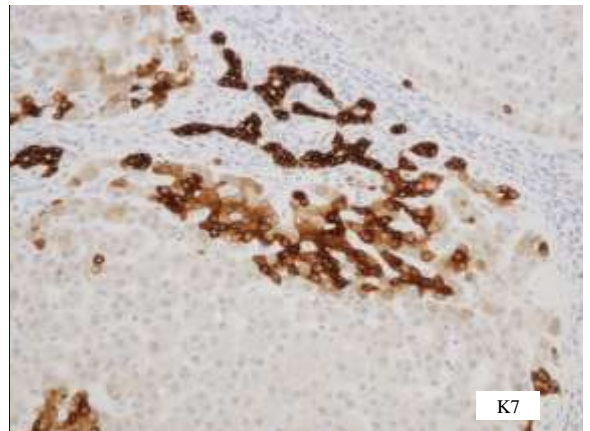
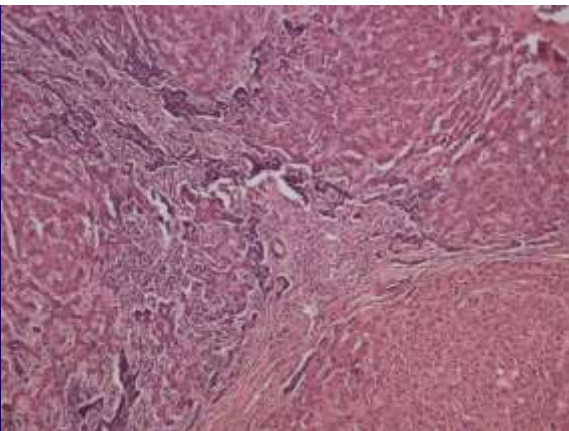
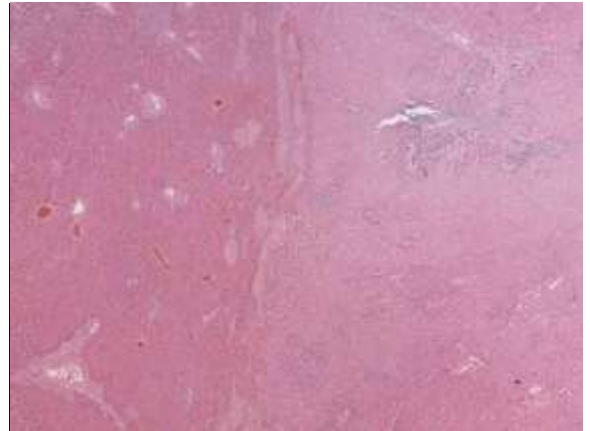
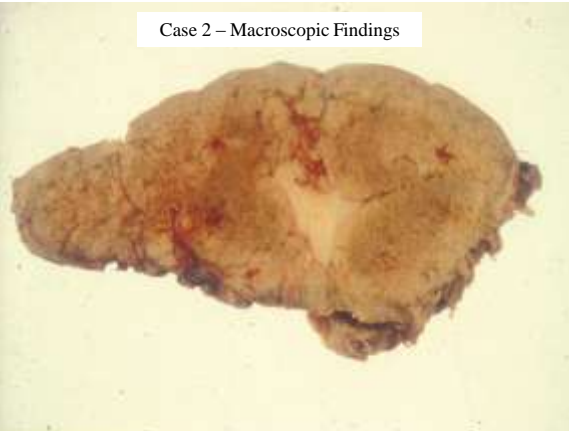Case 2

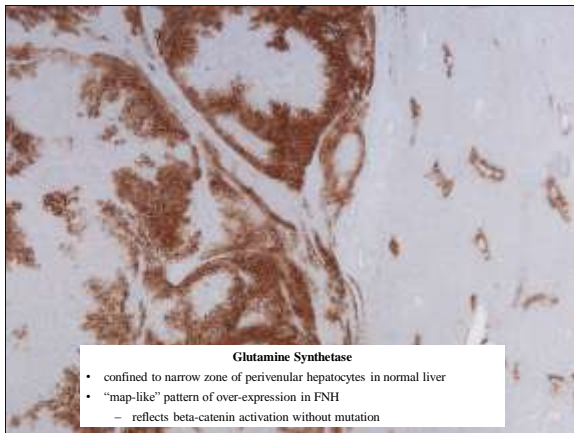
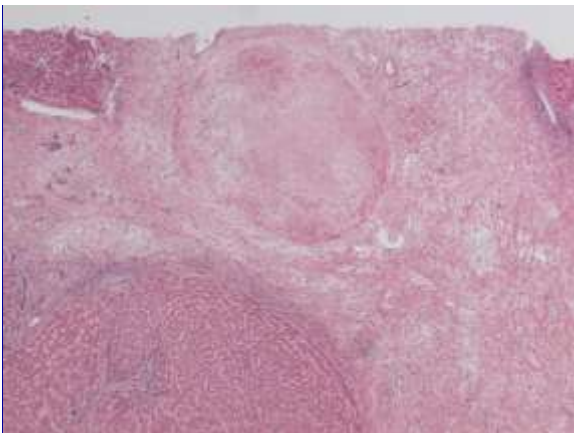
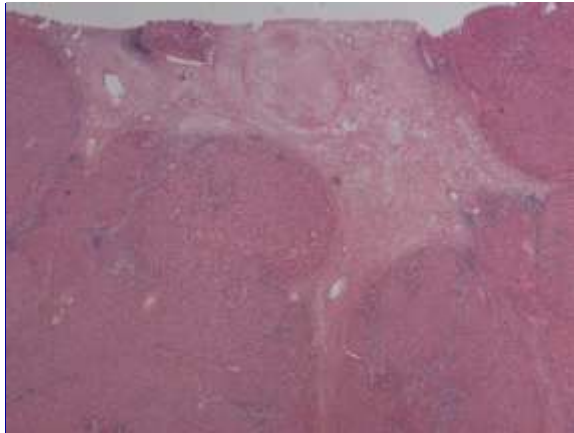
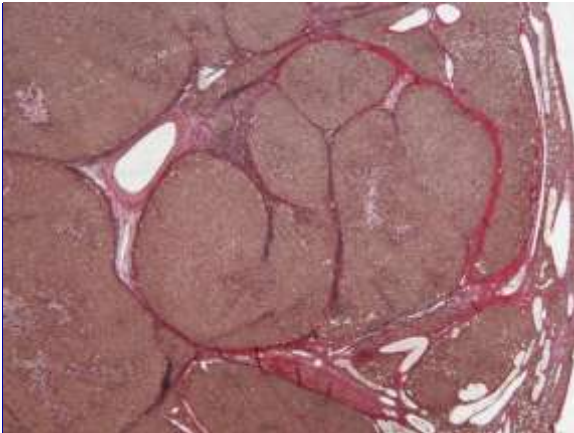
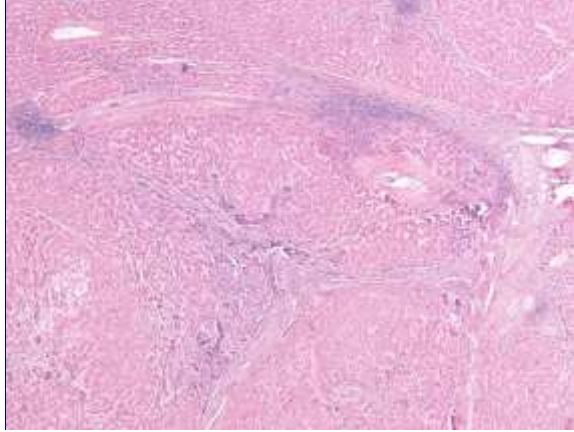
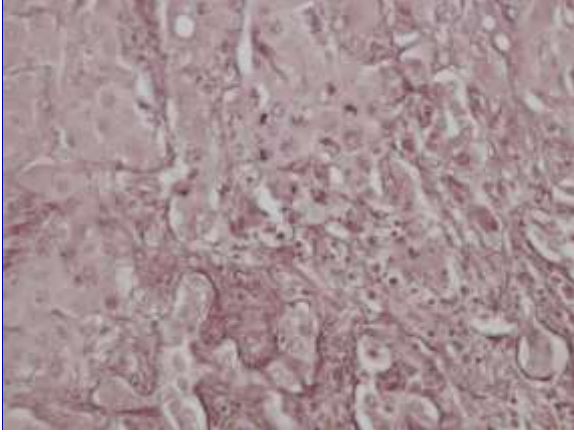
Case 2 - Clinical Summary

Female, age 51

- Liver resection for three lesions in left lobe.
- Main lesion 8cm
 - histology = hepatocellular adenoma
- Slide submitted is from a 4.5cm lesion, which had an irregular central scar
- (3rd lesion 1.5cm diameter had similar histological appearances to lesion 2, but lacked a central scar)

Case 2 – Macroscopic Findings





Glutamine Synthetase

- confined to narrow zone of perivenular hepatocytes in normal liver
- "map-like" pattern of over-expression in FNH
 - reflects beta-catenin activation without mutation

Case 2 – Histological Findings

- Well-differentiated hepatocellular lesion, showing no cytological atypia
- Central fibrous scar containing abnormal blood vessels
- Radiating fibrous septa containing arteries (without bile ducts), inflammatory cells and marginal zones of ductular reaction
- “Map-like” overexpression of glutamine synthetase

Case 2 – Diagnosis

Focal Nodular Hyperplasia

Case 2 – Discussion Points

1. Pathogenesis of FNH

- Response to altered blood flow (increased arterial flow)
 - ? Hepatic or portal venous injury as primary event
 - Congestion and parenchymal collapse (fibrous septa)
 - Arterio-venous shunting and hyper-arterialisation (loss of portal veins and bile ducts)
- May be primary or secondary

Type	Pathogenesis / Histological Features
Primary	<ul style="list-style-type: none"> • Primary vascular abnormality (congenital or acquired) • Central scar with abnormal blood vessel(s)
Secondary	<ul style="list-style-type: none"> • FNH-like changes present in association with vascular abnormalities related to other liver diseases (focal or diffuse): <ul style="list-style-type: none"> – Focal lesions – e.g. haemangioma, hepatocellular adenoma – Diffuse disease – e.g. Cirrhosis, Budd-Chiari syndrome • May have different features to primary FNH (Rebouissou 2008)

Case 2 – Discussion Points

2. Problems with liver biopsy interpretation

- Features of FNH can mimic other liver diseases
 - Cirrhosis
 - Chronic biliary disease with bile duct loss
 - Nearby space-occupying lesion

Case 2 – Discussion Points

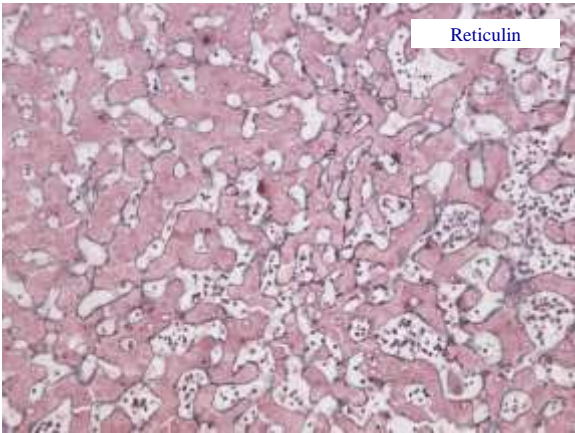
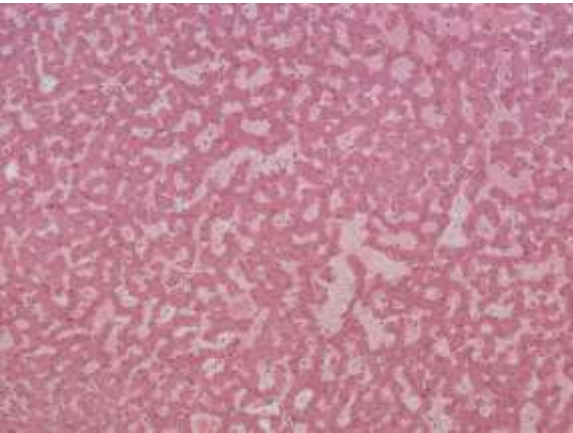
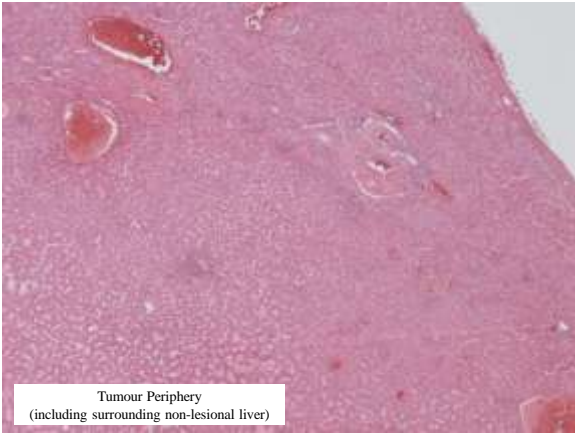
3. FNH versus Hepatocellular Adenoma

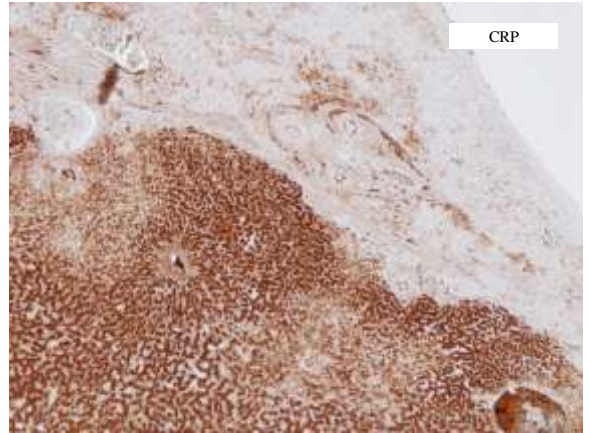
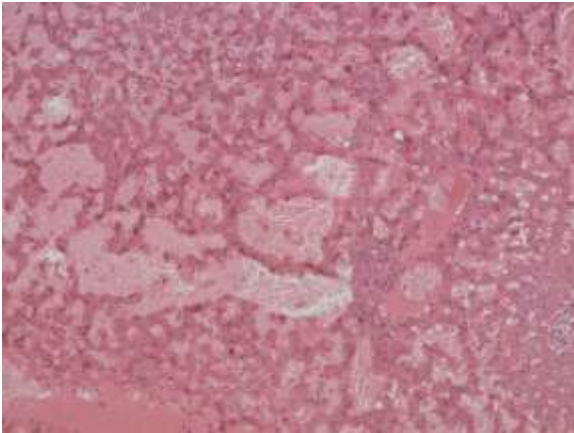
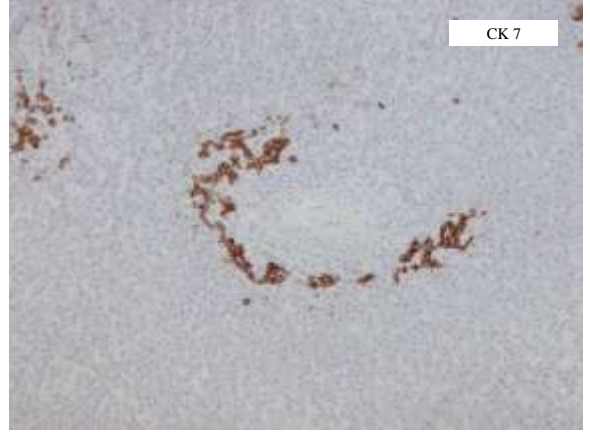
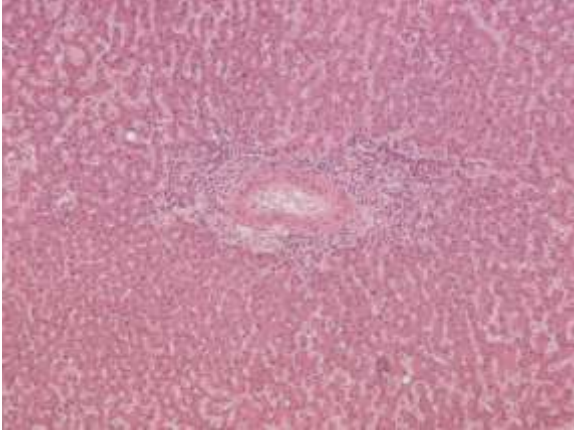
	FNH	HCA
Central Scar	Yes (contains abnormal blood vessels) Some FNH, especially small lesions, may lack clearly identifiable scar	No Foci of fibrosis related to old haemorrhage/necrosis
Nodular Growth Pattern	Typical	Indistinct
Ductular Reaction	Yes (related to fibrovascular septa, inflammatory cells often present)	Not usually (arterial branches +/- fibrous tissue present without ductules) Inflammatory sub-type may contain foci of DR & inflammation (previously classified as “telangiectatic FNH”)
Glutamine synthetase expression	“Map-like” distribution adjacent to hepatic veins	Mostly negative or perivascular (diffusely positive in beta-catenin mutated HCA)

Case 3 - Clinical Summary

Female, age 37

- Left lobe resection for 10 cm mass bulging from surface.
- Slide submitted is from periphery of lesion to include adjacent non-neoplastic liver tissue.





Serum Amyloid A (SAA)

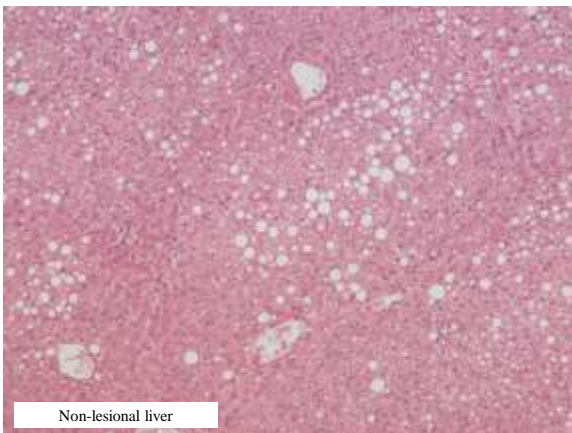
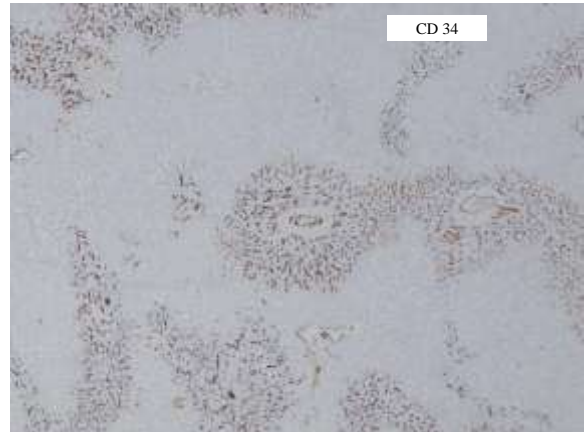
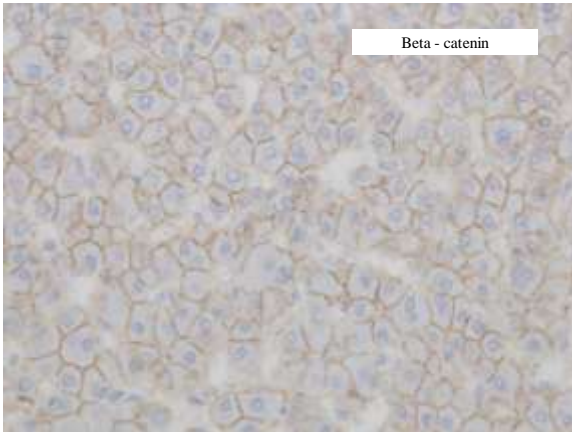
Tumour Non-lesional liver

A comparison of Serum Amyloid A (SAA) staining. The left panel, labeled "Tumour", shows a light blue background with minimal brown staining. The right panel, labeled "Non-lesional liver", shows a similar light blue background with minimal brown staining, indicating low SAA levels in both tissues.

Glutamine Synthetase

Tumour Non-lesional liver

A comparison of Glutamine Synthetase staining. The left panel, labeled "Tumour", shows brown staining in several tubular structures. The right panel, labeled "Non-lesional liver", shows brown staining in several tubular structures, indicating positive staining in both tissues.



Case 3 – Histological Findings

- Well-differentiated hepatocellular lesion
- Fibrovascular structures containing foci of inflammation and ductular reaction
- Sinusoidal dilatation and peliosis
- No cytological atypia. Reticulin framework well preserved.
- Immunohistochemistry
 - Diffuse CRP and SAA expression favours inflammatory phenotype
 - No features to suggest beta-catenin mutation
- Uninvolved liver shows mild fatty change (probably NAFLD – BMI 33)

Case 3 – Diagnosis

- Hepatocellular adenoma (inflammatory subtype)
- No evidence of malignancy
- Arising in background of fatty liver (metabolic syndrome)



Hepatocellular Adenoma – Molecular Classification (Bioulac-Sage et al)

1. Molecular studies have sub-classified HCAs according to different gene mutations
2. Subsequent studies, using resection specimens, have shown that these HCA subtypes have different clinico-pathological features and immunostaining profiles
3. Immunophenotypic characterisation may also be possible in liver biopsy specimens
4. Findings may be relevant for clinical management – e.g. identifying lesions with an increased risk of malignant transformation

Liver Cell Adenoma
Recent Developments in Genotypic and Phenotypic Classification
(Broilac Sage 2011)

Adenoma Subtype	Frequency	Molecular Alterations	Immuno-phenotype	Clinico-pathological features	Malignant potential
HNF1 α Inactivated (H-HCA)	30-35%	Hepatocyte nuclear factor 1 α inactivation	Absent staining for liver fatty acid binding protein (LFABP)	Marked steatosis (due to lack of LFABP)	Very low
β -catenin activated (b-HCA)	5-10%	β -catenin activation	Nuclear β -catenin Glutamine synthetase	More common in men Cytological atypia, pseudoglandular formation	Up to 40%
Inflammatory (IHCA)	50-60%	IL-6 /STAT3 activation	Serum amyloid A C-reactive protein	Sinusoidal dilation ("telangiectatic") & abnormal vessels Inflammatory infiltrates Ductular reaction (FNH-like) Associated with metabolic syndrome & steatosis in background liver β -catenin mutation in up to 10%	Low (increased in male patients, obesity, β -catenin activation)
Unclassified	< 10%				

Beta-Catenin Mutated Liver Cell Neoplasm

Beta – catenin
(nuclear expression)

Glutamine Synthetase
(Diffuse expression vs perivascular in non-lesional liver)

Male, age 31

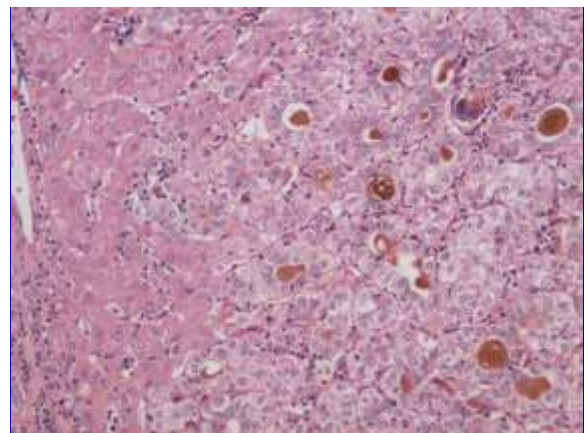
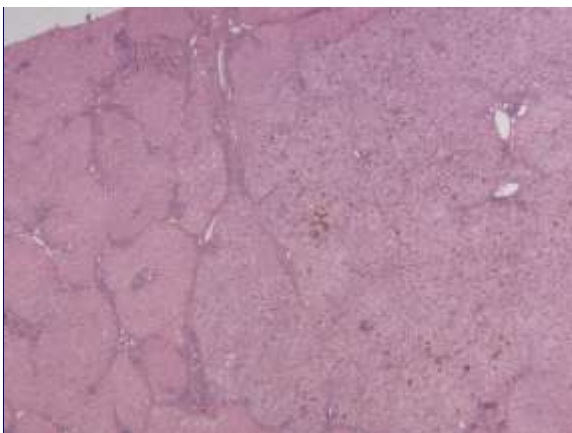
- 11 cm mass in right lobe of liver
- Well differentiated hepatocellular lesion with no cytological atypia
- Presence of focal reticulin fibre loss, glypican 3 positivity, diffuse sinusoidal CD34 expression suggestive of well-differentiated HCC
- Some "atypical adenoma-like neoplasms" of uncertain malignant potential may be difficult to classify (Evason 2013, Bedossa 2014, Balabaud 2015)

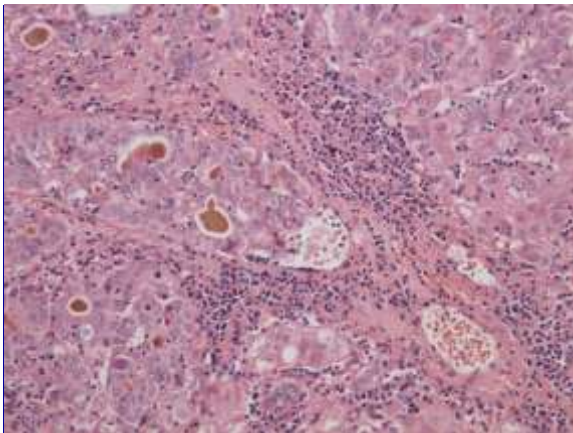
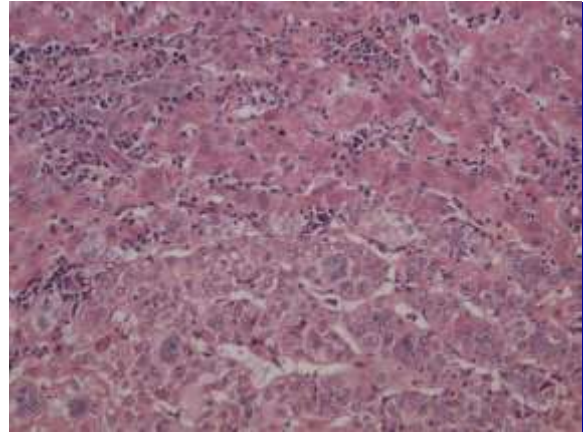
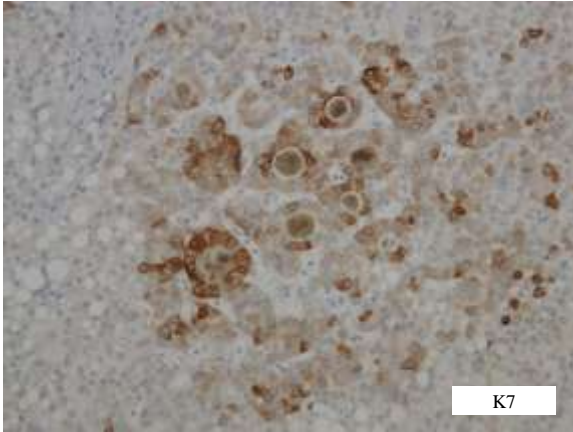
Case 4

Case 4 – Clinical Summary

Male, age 45

- Liver transplantation for autoimmune hepatitis
- Incidental nodule 1.2cm diameter in right lobe of liver





Case 4 – H & E findings

Well-differentiated hepatocellular lesion showing:

- Cytological atypia
 - increased N/C ratio, nuclear crowding, mild nuclear pleomorphism
- Architectural atypia
 - thick plates (> 3 cells thick), glandular structures
- Probable microvascular invasion

➤ Sufficient to warrant a diagnosis of well-differentiated HCC (versus large cirrhotic nodule or dysplastic nodule)

- What additional stains may be helpful in the biopsy diagnosis of early / well-differentiated HCC?
 - Particularly applies to small lesions (1-2cm) where radiological findings are inconclusive

Assessment of Well-differentiated Hepatocellular Lesions - Reticulin Staining

Cirrhotic nodule – normal pattern

Problems with Reticulin Staining in HCC

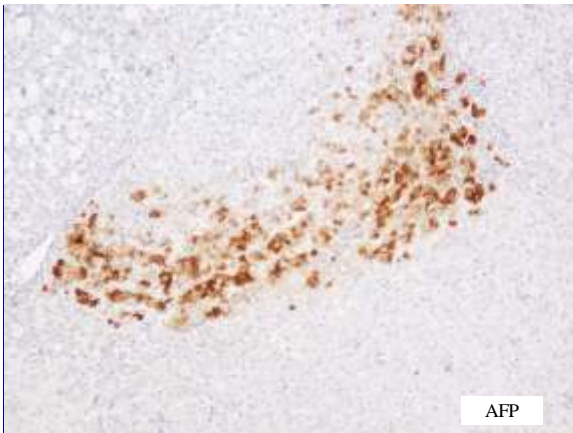
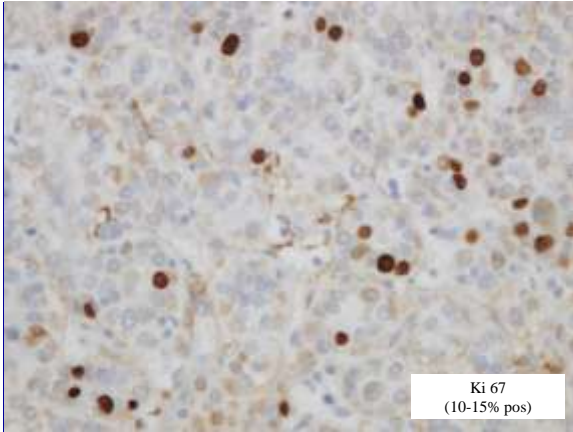
- Reticulin fibres may be preserved in well-differentiated/early HCC
- Focal reticulin fibre loss may occur in benign liver disease
 - e.g. Fatty liver disease (Singhi 2012)
 - Steatotic hepatocellular adenoma

Lesional tissue – thick plates

Lesional tissue – loss of reticulin

Benign Versus Malignant Nodules in Cirrhotic Livers
Features Favouring a Diagnosis of Malignancy
“Conventional” Immunohistochemical Markers

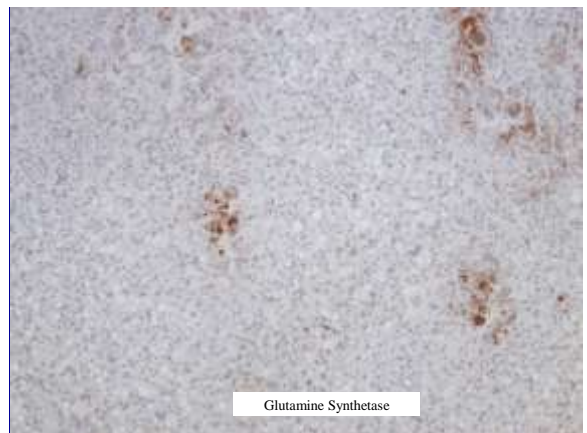
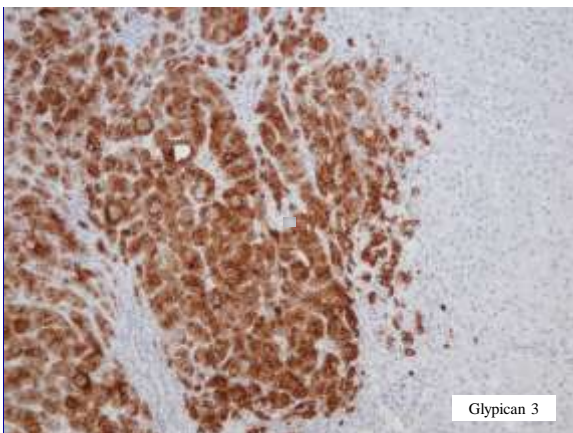
Antibody	Comment
Ki 67	Stepwise increase (cirrhotic nodule – dysplastic nodule – early HCC) No defined threshold for diagnosing HCC Rarely exceeds 5% in well-differentiated HCC
CD34	Diffuse capillarisation of sinusoids (vs focal in cirrhotic nodules) May also occur in high-grade dysplastic nodules (and in FNH & liver cell adenoma)
AFP	Rarely positive in early HCC



Benign Versus Malignant Nodules in Cirrhotic Livers
Features Favouring a Diagnosis of Malignancy
More Recent Immunohistochemical Markers

Molecular studies have identified many genes up-regulated in early HCC
Some have products can be demonstrated immunohistochemically:

Genes/Proteins Upregulated in Early HCC		Immunohistochemistry (criteria for positivity)
Glypican-3	Heparan sulphate proteoglycan Promotes growth of HCC by stimulating Wnt signalling	Cytoplasmic/membranous (> 5-10% of cells)
HSP 70	Chaperone stress protein Potent anti-apoptotic survival factor	Cytoplasmic/nuclear (> 5-10% of cells)
Glutamine Synthetase	Target gene for beta- catenin, GS overexpressed with activation/ mutation of beta-catenin, Involved with hepatocyte regeneration/proliferation	Cytoplasmic (diffuse >50%, unrelated to vessels)



Benign Versus Malignant Nodules in Cirrhotic Livers
Features Favouring a Diagnosis of Malignancy – Recent Immunohistochemical Markers

Application (Glypican-3, HSP 70, Glutamine Synthetase)

- None has 100% specificity or sensitivity individually
- Panel of antibodies improves diagnostic accuracy
 - $\geq 2/3$ positive - 100% specificity & 60-70% sensitivity for HCC
(Di Tommaso 2009, Tremosini 2012)

Limitations

1. Reproducibility of staining methods
2. Conventional histology remains the "gold standard"
 - Studies investigating new antibodies use routine histological assessments to define dysplastic nodules and early/well-differentiated HCC
 - Immunohistochemical panel should only be used as an adjunct to conventional histological assessment

Case 4 – Diagnosis

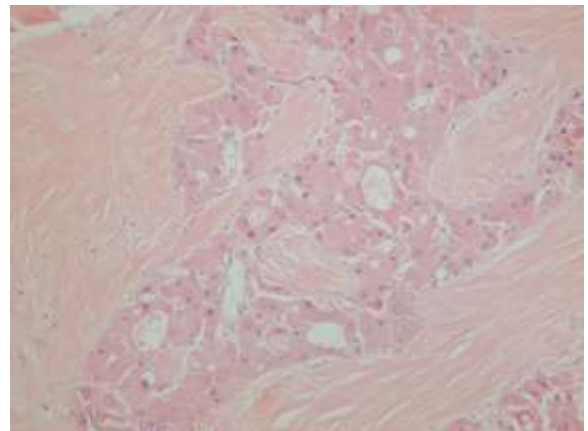
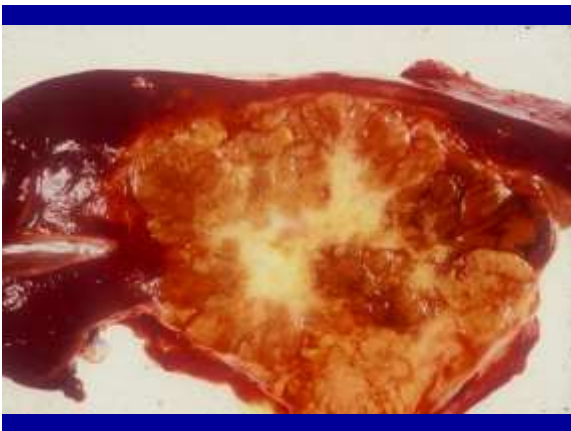
Hepatocellular carcinoma (well-differentiated)
arising in a background of cirrhosis (AIH)

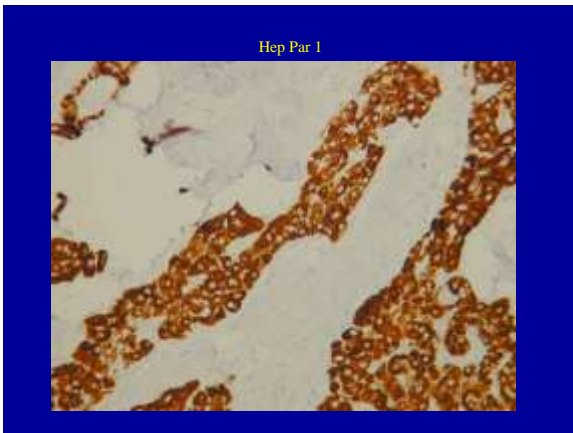
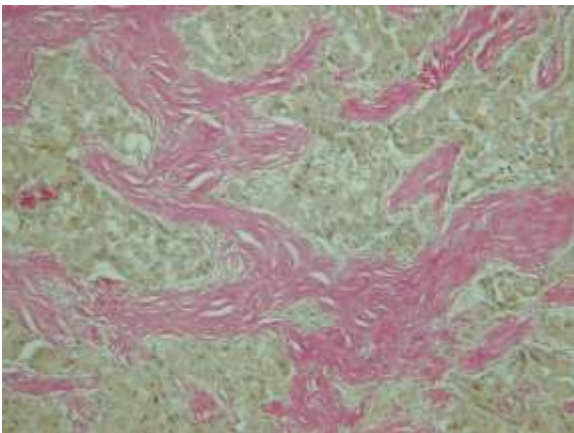
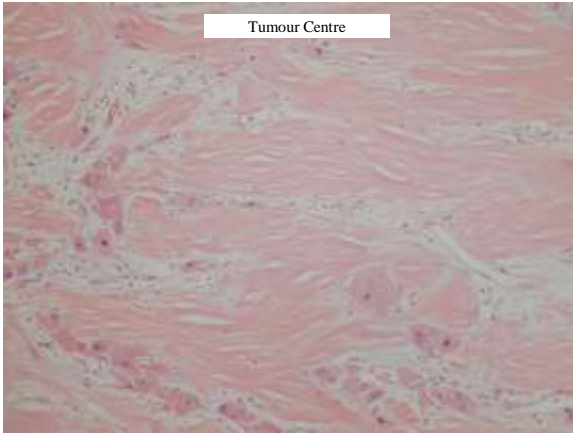
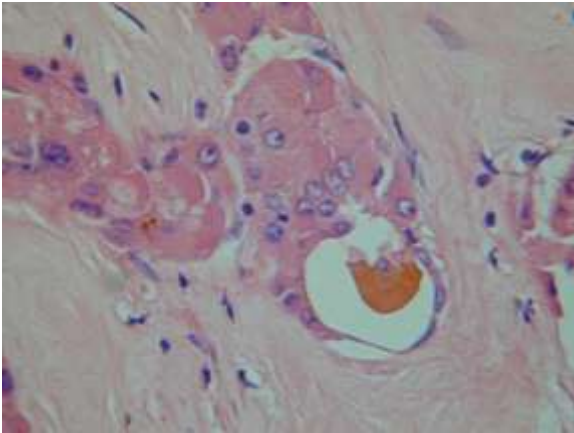
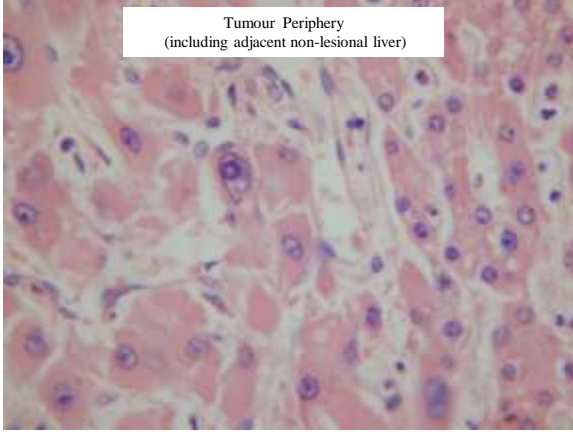
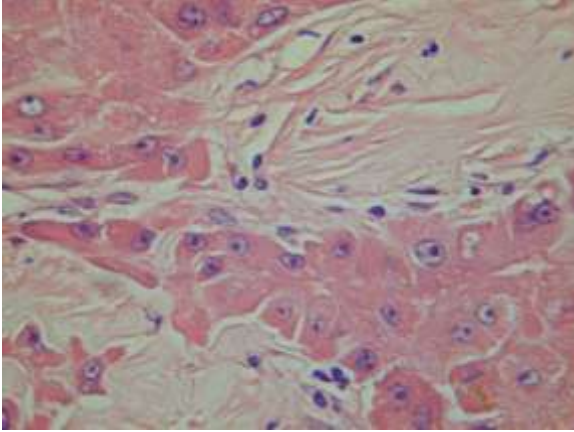
Case 5

Case 5 - Clinical Summary

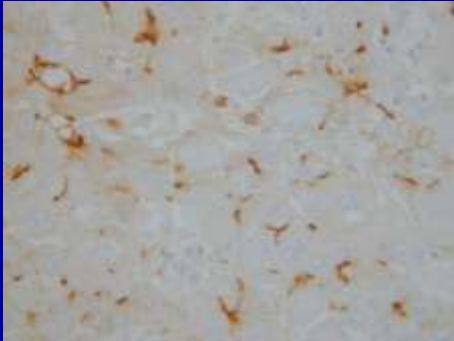
Female, age 26

- Right hemi-hepatectomy specimen.
- Large mass 12 cm diameter with central scar. Enlarged perihilar and coeliac lymph nodes.
- Slide submitted is from periphery of lesion to include surrounding non-neoplastic liver tissue.

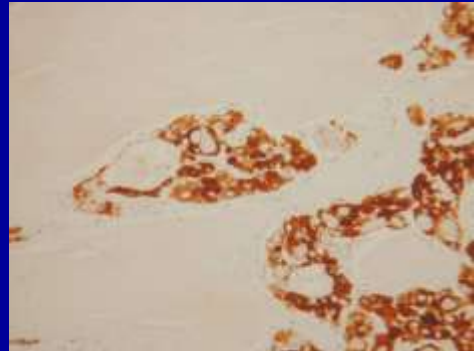




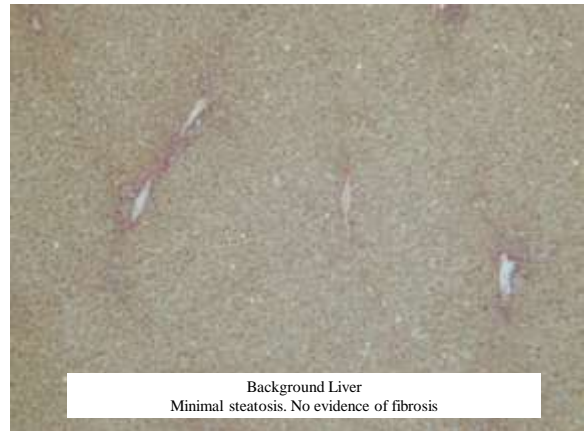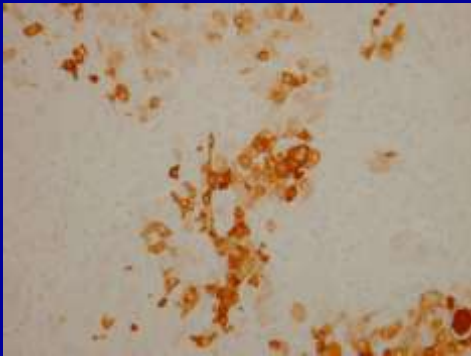
Polyclonal CEA



Mitochondria



CK7



Case 5 – Histological Findings

- Well-differentiated hepatocellular lesion
- Large cells with abundant granular eosinophilic cytoplasm
 - "Oncocytic-like" appearance (due to presence of numerous mitochondria)
- Large nuclei and nucleoli
- Dense stroma arranged as parallel lamellae
 - Most abundant centrally
- Immunostaining positive for Hep Par 1, pCEA (canalicular), mitochondria and CK7

Case 5 – Diagnosis

Fibrolamellar hepatocellular carcinoma

Case 5 – Discussion Points

Fibrolamellar carcinoma versus conventional HCC

1. Clinico-pathological features
2. Tumour biology
3. Problems with histological diagnosis

Fibrolamellar versus Conventional HCC
Clinico-pathological Features

	Fibrolamellar HCC	Conventional HCC
Age	5-35 years (median 20) (second peak, age 60-70 – Eggert 2013)	Most > 50 years
Sex	M=F	M>F
Aetiology	Unknown	HBV, HCV, alcohol, haemochromatosis
Uninvolved liver	Normal	Usually cirrhotic (Cases occurring in non-cirrhotic liver usually have risk factors for chronic liver disease and pre-cirrhotic fibrosis)

Fibrolamellar versus Conventional HCC
Tumour Biology

1. Molecular pathology

- Differences in gene mutations and molecular signalling pathways
e.g. FLC not associated with p53 or beta-catenin mutations, elevated AFP or elevated survivin expression (Liu 2009, Malouf 2012)

2. Immunohistochemical phenotype

(Malouf 2009, Vivekanandan 2009, Abdul-AI 2010, Ward 2010, Zenali 2010, Patomi 2011, Ross 2011, Goodman 2012, Patomi 2013)

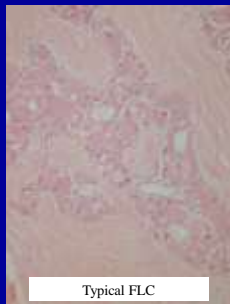
- FLC more frequently expresses CK 7, EMA
– also CD 133 and CD 68, anterior gradient 2, EGFR
- FLC less frequently expresses AFP, beta –catenin, CK 19
- Hep Par 1, pCEA (canalicular) and CD34 (sinusoidal) typically present in both FLC and conventional HCC

Fibrolamellar HCC - Problems with Histological Diagnosis

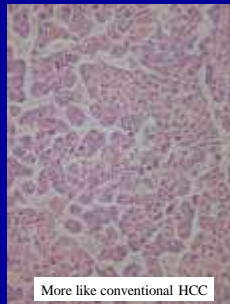
1. FLC may contain areas resembling conventional HCC

- Mixed features of FLC and HCC present in up to 25% cases initially diagnosed as FLC (Malouf 2012)
- Cases of “mixed FLC” more frequently occur in older people, have higher AFP levels and worse prognosis .
- Different patterns of recurrence /metastases (mixed FLC – intrahepatic, pure FLC – extrahepatic)

Mixed features of fibrolamellar and conventional HCC



Typical FLC



More like conventional HCC

Fibrolamellar HCC - Problems with Histological Diagnosis

2. Conventional HCC may contain areas with a resemblance to FLC (sclerosing or scirrhous HCC)

- Cases of HCC occurring in non-cirrhotic liver may be variant of intrahepatic cholangiocarcinoma (or mixed HCC/CC)
 - Stroma loose and cells smaller than in FLC
- Typical HCCs in cirrhotic liver may contain foci with cytological features and/or stroma resembling FLC
 - Infrequent case reports
 - Functional significance uncertain

