

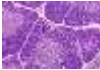





























day 1 afternoon, November 5th 2014








Thymoma and differential diagnosis, other mediastinal tumours

Case 1	Male 57, thymic tumour		B2
Case 2	Male 61, thymic tumour		B1
Case 3	Female, 49, tumour anterior mediastinum		AB (spindle cell thymoma >10% TdT+ lymphocytes)
Case 4	Female, 51, tumour anterior mediastinum		B3
Case 5	Male, 50, thymic mass		Atyp A "A3"
Case 6	Male, 43, mass superior mediastinum		Paraganglioma
Case 7	Female, 60, tumour anterior mediastinum		Thymic carcinoid
Case 8	Male, 45, thymic tumour. Stage?		AB, Masaoka IIa
Case 9	Female, 38, thymectomy for myasthenia		Follicular thymic hyperplasia
Case 10	Female, 33, tumour anterior mediastinum		Castleman
Case 11	Female, 44, thymic tumour		Micronodular thymoma with lymphoid stroma
Case 12	Male, 60, tumour anterior mediastinum		Thymic carcinoma
Case 13	Female, 16, mass in mediastinum, 5,5cm		NUT
Case 14	Male, 63, incidentally discovered mediastinal / thymic nodule during bypass surgery		Multilocular thymic cyst with squamous metaplasia
Case 15	Male, 64, thymic tumour		Metaplastic thymoma

Sarajevo BD-IAP 2014 Slide seminar thymic & mediastinal pathology

Case 16	Male, 68, wedge resection lung, previous history mediastinal mass		metastasectomy type A thymoma
Case 17	Male, 51, anterior mediastinal mass		Thymic cyst Probably with solitary fibrous tumour!
Case 18	Male, 42, huge mass in anterior mediastinum, few complaints		Thymolipoma
Case 19	Female, 67, Tumor in posterior mediastinum, attached to aortic arch and vagus nerve, present for a long time		hemangioendothelioma (angioma) with lipomatous component
Case 20	Female, 20, mediastinal and pleural mass		epithelioid hemangioendothelioma
Case 21	Male, 82, Mediastinal mass fixed to lung and pericardium, encapsulated		Solitary fibrous tumour
Case 22	Female, 24, tumour in the posterior mediastinum		Monophasic synovial sarcoma
Case 23	Male, 56, Mediastinal mass		Schwannoma
Case 24	Female, 45, tumour in the mediastinum extending to diaphragm		Ganglioneuroma
Case 25	Female, 23, tumour in posterior mediastinum		Ganglioneuroma
Case 26	Female, 11 months, tumour in mediastinum, post chemotherapy		(Maturing) Ganglioneuroblastoma
Case 27	Male, 15, mediastinal mass and multiple lung nodules		Choriocarcinoma
Case 28	Male 18, mediastinal tumour		Embryonal carcinoma
Case 29	Male, 14, central mediastinal mass		Osteosarcoma Query-non secondary non-GCT?
Case 30	Male, 40, mediastinal tumour. High LDH, night sweats		Sclerosing mediastinal B-cll lymphoma

Sarajevo BD-IAP 2014 Slide seminar thymic & mediastinal pathology

Test case 1	Male, 64, mediastinal mass		Micronodular thymoma
Test case 2	Female, 26, Centrally located mediastinal tumour between aorta and trachea, 5,5cm. Pre-operative diagnostic attempts unsuccessful, primary resection		Castleman Same slide as case 10
Test case 3	Male, 44, central mediastinal mass		Schwannoma
Test case 4	History of coronary bypass graft. Abnormal structure in superior mediastinum		Thymic carcinoma
Test case 5	Male, 59. Thymic tumour		B3
Test case 6	Male, 35, mediastinal mass, 16cm		thymic carcinoid NB history of hyperparathyroidism (MEN-1)
Test case 7	Male 50, mediastinal tumour		Choriocarcinoma

Literature

Journal of Thoracic Oncology – Sept 2014 Volume 9 supplement 2

A special issue on Thymoma and mediastinal pathology

Articles available FREE

<http://journals.lww.com/jto/toc/2014/09002>

Histologic Classification of Thymoma: A Practical Guide for Routine Cases
den Bakker MA, Roden AC, Marx A, Marino M J Thor Oncol (2014) 9(9) S125-S130

ITMIG consensus statement on the use of the WHO histological classification of thymoma and thymic carcinoma: refined definitions, histological criteria, and reporting. Marx et al., J Thorac Oncol. 2014 May;9(5):596-611.

Classifying thymomas Addis B & den Bakker M Histopathology. 2008
May;52(6):759-66.

Tumours and tumour-like conditions of the thymus other than thymoma; a practical approach. den Bakker MA1, Oosterhuis JW. Histopathology (2009)
54(1):69-89.